Respiratory Bronchiolitis/Interstitial Lung Disease

Fibrosis, Pulmonary Function, and Evolving Concepts

Andrew Churg, MD; Nestor L. Müller, MD, PhD; Joanne L. Wright, MD

• ***Context.*—The concept of respiratory bronchiolitis/interstitial lung disease (RBILD) was introduced to explain the presence of interstitial lung disease in individuals whose only finding on surgical lung biopsy was smoker's respiratory bronchiolitis (RB). Over time, the diagnostic criteria for RBILD have become progressively more confused.**

***Objective.*—To review the diagnostic criteria for RBILD.**

***Design.*—The review was based on the literature and personal experience.**

***Conclusions.*—The concept of RBILD has changed over time with the recognition that, histologically and radiologically, RB and RBILD are usually indistinguishable. Most authors accept mild alveolar wall fibrosis extending away from the respiratory bronchioles as a part of both RB and RBILD, and occasional cases show quite marked, but probably localized, interstitial fibrosis. What has not been appreciated is that RB is not only an extremely common disease in cigarette smokers but also is ordinarily associated with airflow obstruction. Further, interstitial fibrosis is sometimes found in centrilobular emphysema, and this phenomenon has probably lead to some cases of centrilobular emphysema being misclassified as RB or RBILD. Despite the presence of fibrosis, centrilobular emphysema is still associated with airflow obstruction. We suggest that RBILD be restricted to the clinical setting in which cigarette smokers have a restrictive or mixed obstructive and restrictive functional abnormality, have a marked decrease in diffusing capacity with minimal evidence of airflow obstruction, or have imaging studies showing ground glass opacities/centrilobular nodules plus reticulation and no other lesion besides RB on biopsy to account for these changes. In this setting, the presence of RB-associated interstitial fibrosis probably causes the functional changes.**

(*Arch Pathol Lab Med.* 2010;134:27–32)

The concept of respiratory bronchiolitis/interstitial lung disease (RBILD) was introduced in 1987 by Myers et al[1] as a morphologic explanation for clinical interstitial lung disease (explicitly, in their article, restrictive pulmonary function tests and/or interstitial markings on plain chest radiographs) in 6 patients in whom nothing besides smoker's respiratory bronchiolitis (RB) could be found on surgical lung biopsy. Since that time, there have been few cases reported, and arguments continue back and forth about what histologic features, what radiologic features, and what clinical features define this condition,[2] and the diagnostic criteria have become progressively murkier. Indeed, Wells et al[3] have concluded that the diagnosis of RBILD ''remains a nebulous gestalt of clinical, functional, and HRCT [high-resolution computed tomography] findings. . . . ''

Respiratory bronchiolitis/interstitial lung disease and smoker's RB are diseases of cigarette smokers (with 1 exceptional case, to our knowledge, occurring in a nonsmoker exposed to solder flux).[4] Cases reported as RBILD are associated with heavy smoking (mean pack-years ranging from 29 to 54 in published series[1,4–7]), and this, of course, makes such patients candidates for chronic obstructive pulmonary disease (COPD), a process that potentially confounds the diagnosis of RBILD pathologically, radiologically, and on pulmonary function testing. Morphologic lesions of COPD, where reported, are indeed common; for example, 9 of 10 patients with RBILD (90%), described by Moon et al,[4] had centrilobular emphysema (see comments below on imaging).

We were asked to specifically address the issue of fibrosis and its significance in RBILD in this brief review, but in doing so, it has become apparent that there are 2 pools of knowledge: 1 related to interstitial lung diseases and their pathologic correlates, and the other related to COPD and its pathologic correlates. Here, we attempt to put these 2 schools together and to suggest what this means for diagnosing RBILD.

MORPHOLOGIC FINDINGS IN RBILD

In the original article of Myers et al,[1] the major pathologic finding was the presence of RB: clusters of slightly golden colored alveolar macrophages (''smoker's macrophages'') in the lumens of respiratory bronchioles, alveolar ducts, and in the surrounding alveoli. Some of the bronchioles and adjacent alveoli walls also demonstrated a mild chronic interstitial inflammatory infiltrate as well as interstitial fibrosis and hyperplasia of the overlying alveolar epithelial cells. Myers et al[1] suggested that extension

Accepted for publication September 22, 2008.

From the Department of Pathology, University of British Columbia, Vancouver, Canada (Drs Churg and Wright); and the Department of Radiology, Vancouver General Hospital (Dr Müller).

The authors have no relevant financial interest in the products or companies described in this article.

Reprints: Andrew Churg, MD, Department of Pathology, University of British Columbia, 2211 Westbrook Mall, Vancouver, BC V6T 2B5, Canada (e-mail: achurg@interchange.ubc.ca).

Downloaded from https://aplm.kglmeridian.com at 2026-03-06 via free access

Table 1. Pathologic Features Reported in Respiratory Bronchiolitis/Interstitial Lung Disease (RBILD) and Respiratory Bronchiolitis (RB)

Source, y	Fibrosis/Inflammation in Walls of RB	Mild Fibrosis Alveolar Walls Around RB	Fibrosis Away From RB	Dense Alveolar Wall Fibrosis
RBILD studies				
Myers et al,[1] 1987	+ (fibrosis and inflammation)	+ (also inflammation and large alveolar lining cells)		
Yousem et al,[5] 1989	+	+ (mild only)	No	
Moon et al,[4] 1999	+			
Ryu et al,[6] 2005	Only smoker's macrophages	? No (definition unclear)		
Yousem et al,[9] 2006			+	+
Portnoy et al,[7] 2007	+	+	No	
RB studies				
Fraig et al,[11] 2002				
Current smokers (n = 83)				Some dense fibrosis but may be emphysema
Fibrosis, No. (%)	none, 38 (46)	+ 37 (45)		
Inflammation, No. (%)	+ 8 (10)			
Ex-smokers (n = 24)				
Fibrosis, No. (%)	none, 13 (54)	+ 10 (42)		
Inflammation, No. (%)	+ 1 (4)			
Yousem et al,[9] 2006				
Lung resections (n = 30), No. (%)	+ 17 (57) as only finding	+ 6 (20)	+ 4 (14)	+ 3 (10)

of the fibrosing and inflammatory process into adjacent alveolar walls separated RBILD from RB. However, the major impetus for the original description of RBILD was to separate what appeared to be a relatively benign form of interstitial lung disease from usual interstitial pneumonitis, the diagnosis with which a number of the original cases had been referred for consultation[8] (J. L. Myers, oral communication, September 2007).

Subsequent pathologic descriptions of RBILD have reported largely similar findings (Table 1; Figures 1 through 4), albeit with some variation from report to report and also with incorporation of the changing definitions of RB (see below). All of the studies listed in Table 1 have used the presence of smoker's macrophages as a fundamental requirement for diagnosing RBILD. Some, such as Ryu et al,[6] appear to accept cases with nothing more than smoker's macrophages (albeit this report does not provide pathologic details), but most authors have noted that the walls of the respiratory bronchioles are fibrotic in RBILD and may also contain inflammatory cells,[1,4,5,7,8] and most have also included fibrosis and inflammation in the alveolar walls surrounding respiratory bronchioles as part of the morphologic spectrum of this disease.

More recently Yousem[9] reported on 9 patients with the basic morphologic features of RBILD but with quite marked alveolar wall fibrosis (Figure 5). These cases were selected from a series of consultation cases referred with a diagnosis of fibrotic nonspecific interstitial pneumonia. The fibrosis appeared to radiate from the affected bronchioles and extended to the pleura but did not produce architectural distortion. The process was paucicellular and was described as lamellar or amyloid-like. Some cases showed focal areas with distal airspaces filled by alveolar macrophages in a pattern resembling desquamative interstitial pneumonia. Yousem[9] made the point that the smoker's macrophages, the radiating distribution of the lesions, the dense lamellar collagen, and the desquamative interstitial pneumonia-like areas were not typical of nonspecific interstitial pneumonia, and, most important, the prognosis was considerably better than that of fibrotic nonspecific interstitial pneumonia (Table 2).

The imaging changes in these 9 cases were not any different from what has been reported in other cases of RB/RBILD (see below). Pulmonary function test data were available for 4 patients (44%) and was reported as mixed obstructive and restrictive but primarily obstructive disease. These observations suggest that this type of fibrosis, although dramatic in a surgical lung biopsy, is probably a very localized phenomenon that has limited functional consequences.

→

Figure 1. *Respiratory bronchiolitis/interstitial lung disease (RBILD) in a 44-year-old woman. Note the distinctly fibrotic walls of the respiratory bronchioles and the aggregates of lightly pigmented, smoker's macrophages in the bronchiolar lumens and surrounding alveolar spaces. This particular example does not show fibrosis in the alveolar walls radiating from the respiratory bronchioles. Pathologically, this could be respiratory bronchiolitis or RBILD, but the patient had a mixed obstructive and restriction pattern of pulmonary function, indicating that the correct diagnosis is RBILD (hematoxylin-eosin, original magnification ×50).*

Figure 2. *Higher-power field view of the same case shown in Figure 1, illustrating the fibrotic bronchiolar walls and the collections of smoker's macrophages (hematoxylin-eosin, original magnification ×200).*

Figure 3. *Another case of respiratory bronchiolitis/interstitial lung disease (RBILD), illustrating fine interstitial fibrosis in the alveolar walls around the respiratory bronchioles. Collections of smoker's macrophages are again present. The diagnosis of RBILD was made based on pulmonary function tests; morphologically, this could be respiratory bronchiolitis or RBILD (hematoxylin-eosin, original magnification ×100).*

Downloaded from https://aplm.kglmeridian.com at 2026-03-06 via free access

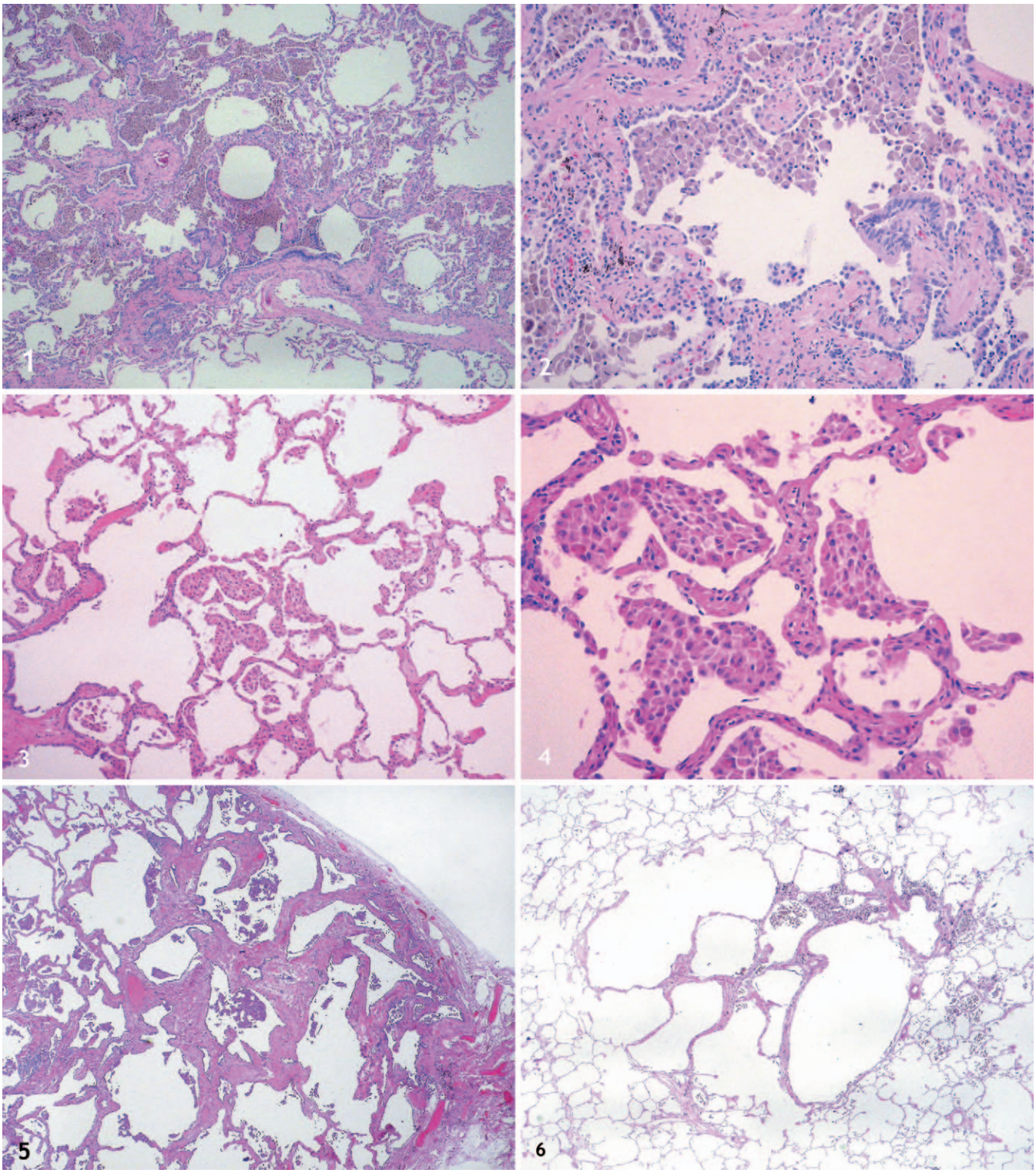

Figure 4. *Higher-power field view of case shown in Figure 3, illustrating the paucicellular interstitial fibrosis and smoker's macrophages (hematoxylin-eosin, original magnification ×200).*

Figure 5. *A case of respiratory bronchiolitis/interstitial lung disease with much more marked, dense, paucicellular fibrosis and collections of smoker's macrophages in airspaces, producing a picture focally reminiscent of desquamative interstitial pneumonia (hematoxylin-eosin, original magnification ×50).*

Figure 6. *Centrilobular emphysema with fibrosis. Some of the smaller central spaces with smoker's macrophages in the lumen could represent residual respiratory bronchioles, but the larger spaces are destroyed parenchyma (emphysema) and not respiratory bronchioles (hematoxylin-eosin, original magnification ×50).*

Downloaded from https://aplm.kglmeridian.com at 2026-03-06 via free access

Table 2. Pulmonary Function in Cases of Respiratory Bronchiolitis/Interstitial Lung Disease						
Source,[a] y	Cases, No.	Restrictive, No. (%)	Obstructive, No. (%)	Mixed, No. (%)	Isolated Diffusion Defect, No. (%)	Normal Findings, No. (%)
Myers et al,[1] 1987	6	1 (17)		4 (67)	1 (17)	
Moon et al,[4] 1999	6	3 (50)	3 (50)			
Ryu et al,[6] 2005	10	5 (50)	3 (30)		1 (10)	1 (10)
Yousem et al,[9] 2006	4			4 (100)		

[a] Results are from pulmonary function tests reported by the source.

SEPARATION OF RBILD FROM RB

Respiratory bronchiolitis was first described by Niewoehner et al[10] in 1974 as a lesion seen in young cigarette smokers dying accidentally; their description included smoker's macrophages in bronchiolar lumens, fibrosis, and inflammation in the bronchiolar wall and, although this point has been somewhat ignored in descriptions of RBILD, variable amounts of fibrosis in the surrounding alveolar walls. Niewoehner et al[10] viewed all of these abnormal findings as part of the changes seen in smoke-induced COPD, although, as noted above, some of the descriptions of RBILD used fibrosis, particularly alveolar wall fibrosis, as a point of separation from RB.

This convenient distinction was challenged by Fraig et al[11] who examined 156 consecutive lung biopsy specimens and found RB in all 83 current smokers (100%) and 24 of 49 ex-smokers (49%; Table 1). Bronchiolar wall fibrosis was present in 9.5% of the smokers and 4% of ex-smokers, and peribronchiolar alveolar wall fibrosis was present in 45% of the smokers and 42% of the ex-smokers. They made a retrospective diagnosis of RBILD in 1 patient, based on the presence of restrictive pulmonary function tests and commented that the alveolar wall fibrosis in that case was no different from the alveolar wall fibrosis in the patients with RB only.

Yousem[9] performed a similar examination of 30 consecutive lobectomies from cigarette smokers with lung cancer; 17 (57%) had RB without alveolar wall fibrosis, 6 (20%) had mild alveolar wall fibrosis, and 4 (13%) had fibrosis extending to the subpleural regions in a pattern resembling the cases he described[9] with dense lamellar fibrosis. The conclusion from both these studies (more explicitly laid out in Fraig et al[11]) was that there were no histologic features that separated RBILD from RB.

Although acknowledging this idea, some authors still suggest that clinical RBILD is associated with greater degrees of morphologic fibrosis,[3] but whether or not this is true, it appears that many lungs from cigarette smokers do show some (generally mild) alveolar wall fibrosis.

RB AND CENTRILOBULAR EMPHYSEMA: MORPHOLOGY AND FUNCTIONAL CONSEQUENCES IN COPD

In 1968, Hogg and colleagues[12] demonstrated that the major site of airflow resistance was in the airways of less than 2 mm internal diameter. This paradigm suggested that any or all of the small cartilaginous airways and membranous or respiratory bronchioles were structurally altered (*remodeled* in current COPD terminology) in cigarette smokers and that this remodeling induced turbulent flow and increased airway resistance despite the large cross-sectional area of the airways involved.

Various methods have been used to try to quantify either airway remodeling, in general, or changes in the various components of the airway wall, with a view to understanding the morphologic features that correlate with airflow obstruction. The respiratory bronchioles in smokers were not examined until Niewoehner and colleagues[10] developed a grading scheme for the membranous bronchioles and also included an evaluation of RB. Although it varied in intensity and distribution, RB was a consistent feature in all of the smokers examined.

Cosio and colleagues[13] created a pictorial grading scheme for the membranous bronchioles, and Wright et al[14] expanded the grading scheme to involve the respiratory bronchioles and to include separate evaluations of the wall components in addition to intraluminal macrophages. Using this approach, they found that not only did fibrosis and inflammation of the membranous bronchioles correlate with pulmonary function abnormalities related to COPD, including the forced expiratory volume in the first second of expiration (FEV_1) and forced expiratory flow, midexpiratory phase ($FEF_{25\%–75\%}$), but so did, independently, the similar changes in the respiratory bronchioles.[15] These findings suggest that the major and most common effect of RB is to produce airflow obstruction and not restriction.

As noted above, Niewoehner and colleagues[10] observed that the alveolar walls adjacent to the respiratory bronchiole could show fibrosis. However, alveolar wall fibrosis is also seen as a part of coexisting centrilobular emphysema (Figure 6).[16–19] Interestingly, in a study of mild emphysema, altered collagen was found in association with aggregations of pulmonary macrophages.[19] Hogg and colleagues[20] examined the pressure-volume curves of emphysematous lungs and found that the emphysematous holes were actually less compliant than the adjacent lung. Despite the presence of fibrosis, however, the functional consequence of centrilobular emphysema is airflow obstruction.

Foci of centrilobular emphysema can be associated with fibrosis, as is well known to pathologists who work on COPD but is largely unknown outside this group. Emphysematous foci are acknowledged as a common finding in patients with RB/RBILD, and we raise the question of whether some of the descriptions of alveolar wall fibrosis associated with RB or RBILD may really be misclassifications of fibrotic emphysematous foci. This misclassification may provide a partial explanation for why what has been called ''RBILD'' is rarely associated with restrictive pulmonary function tests.

CAN IMAGING SEPARATE RB FROM RBILD?

Most patients with histologically proven RB have no demonstrable parenchymal abnormality on HRCT.[21,22] The HRCT manifestations, when present, consist of poorly defined centrilobular nodules and patchy or confluent, bilat-

Downloaded from https://aplm.kglmeridian.com at 2026-03-06 via free access

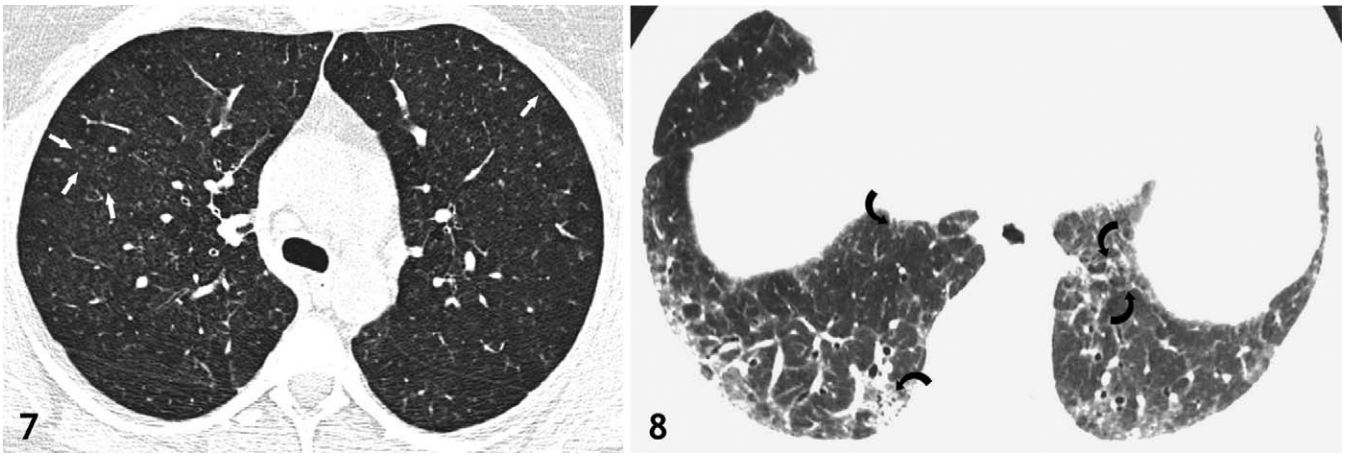

Figure 7. *Respiratory bronchiolitis/interstitial lung disease (RBILD) in a 44-year-old woman. High-resolution computed tomography shows bilateral, poorly defined, centrilobular nodules (arrows) and ground-glass opacities. These findings would be consistent with respiratory bronchiolitis or RBILD (and, of course, other entities in a different clinical context). This is the same case illustrated in Figures 1 and 2.*

Figure 8. *Respiratory bronchiolitis/interstitial lung disease (RBILD) in a 60-year-old male smoker. High-resolution computed tomography shows bilateral ground-glass opacities and mild peripheral reticulation (arrows). These findings are consistent with RBILD but not respiratory bronchiolitis.*

Downloaded from https://aplm.kglmeridian.com at 2026-03-06 via free access

eral, ground-glass opacities.[21–23] These findings can be diffuse but tend to involve mainly the upper lung zones.[21,22]

Similar to RB, the most common HRCT manifestations of RBILD are poorly defined centrilobular nodules and ground-glass opacities. Patients may have one or both findings (Figure 7) or normal-appearing lungs on HRCT.[22,24] The centrilobular nodules and ground-glass opacities may be diffuse or may involve mainly the upper or lower lung zones. Upper-lobe emphysema is commonly present but is usually mild. A small percentage of patients have a reticular pattern because of fibrosis (Figure 8).[22,24,25] The fibrosis in RBILD is mild and tends to involve mainly the lower lung zones. Bronchial wall thickening was described as a common finding in one study[24] but was not mentioned in the other studies.[22,25]

Holt et al[25] described the spectrum of HRCT findings in 5 patients with RBILD. The findings were very variable and ranged from no detectable abnormality to atelectasis, ground-glass opacities, emphysema, and reticular interstitial opacities. Park et al[24] correlated HRCT findings with pathologic findings in 21 patients who had RBILD. All patients were current or former cigarette smokers. The most common HRCT findings were thickening of the bronchial walls (90%; 19 of 21 patients), centrilobular nodules (71%; 15 of 21 patients), and ground-glass opacities (67%; 14 of 21 patients). The centrilobular nodules were more profuse in the upper lung zones in 8 patients (54%; 8 of 15 patients), the middle or lower lung zones in 3 patients (18%; 3 of 15 patients), and had an even distribution in 4 patients (28%; 4 of 15 patients). Areas of ground-glass opacity showed no significant zonal predominance. Other findings included upper-lung–predominant centrilobular emphysema (57%; 12 of 21 patients) and patchy areas of decreased attenuation (38%; 8 of 21 patients) with lower-lung predominance. The extent of centrilobular nodules correlated with the number of macrophages in respiratory bronchioles and with chronic inflammation of respiratory bronchioles, whereas the extent of ground-glass opacity correlated with the amount of macrophage accumulation in the alveoli and alveolar ducts.

Heyneman et al[22] reviewed the HRCT findings in 16 patients with RB (53%), 8 patients with RBILD (27%), and 6 patients with desquamative interstitial pneumonia (20%). The predominant abnormal findings in patients who had RB consisted of poorly defined centrilobular nodules seen in 75% of patients (12 of 16 patients), and ground-glass opacities seen in 38% of patients (6 of 16 patients). The main findings in patients who had RBILD were ground-glass opacities seen in 50% of patients (4 of 8 patients), centrilobular nodules in 38% of patients (3 of 8 patients), and mild fibrosis present in 25% of patients (2 of 8 patients).

In summary, in most cases, the HRCT findings of RBILD are similar to those of RB, consisting mainly of bilateral, poorly defined, centrilobular nodules and ground-glass opacities. Reticulation (indicating underlying fibrosis) has only been described in patients with RBILD (Figure 8). One study[4] reported reticulation in most cases, but in most studies, reticulation is a relatively uncommon finding, thus limiting its usefulness as a diagnostic criterion.

FUNCTIONAL CHANGES AND THE DIAGNOSIS OF RBILD

There is a surprisingly wide spectrum of functional changes reported in patients who reportedly have RBILD (Table 2). These vary from findings of normal function to findings of isolated, decreased diffusing capacity or to findings of obstructive, restrictive, or mixed obstructive and restrictive patterns. This variation brings up the question of how RBILD is defined clinically.

Given the overlapping HRCT appearances of RB and RBILD, except in the small percentage of patients with RBILD who have evidence of fibrosis, it appears to us that only a pulmonary functional definition remains. In that context, it is difficult to understand how a patient with a finding of normal pulmonary function and an HRCT appearance of, for example, ground-glass nodules, which are encountered in asymptomatic smokers, can be claimed to have an interstitial lung disease.

The issue is even more confused when claims are made that patients with RBILD have a pure obstructive pattern because, as noted above, the pathologic features of RB correlate well with obstructive changes. Disproportionate de-

Table 3. Reported Outcomes in Respiratory Bronchiolitis/Interstitial Lung Disease				
Source, y	Cases, No.	Improved, No. (%)	Stable, No. (%)	Worse, No. (%)
Myers et al,[1] 1987	6	5 (83)	1 (17)	0
Yousem et al,[9] 1989	16	13 (81)	3 (19)	0
Moon et al,[4] 1999	9	7 (70)		3 (30)
Yousem et al,[9] 2006	10		7 (78)	2 (22)
Ryu et al,[6] 2005	12	3 (25)	8 (67)	1 (8)
Portnoy et al,[7] 2007	25	14 (56)		11 (44), 1 died of ILD

Abbreviation: ILD, interstitial lung disease.

creases in diffusing capacity, which have also been suggested to be typical of RBILD,[3] may be useful as a guide to diagnosis, but only if the patient does not have significant emphysema or small airway remodeling because both of these lesions are well recognized causes of decreases in diffusing capacity.[26–28]

Thus, it appears to us that, except for cases in which imaging studies show reticulation on HRCT, only restrictive or mixed restrictive/obstructive patterns, or (less certainly) a markedly reduced diffusing capacity in the absence of evidence of significant airflow obstruction, allow the diagnosis of RBILD. It is tempting to speculate that these patients have diffuse fibrosis or more severe fibrosis, but at this point, such a conclusion is just speculation because no correlative studies exist.

This does not mean that there is no role for the pathologist. The original approach of Myers et al[1] still stands: the diagnosis of RBILD on biopsy requires the presence of RB and the exclusion of other forms of interstitial lung disease.

PROGNOSIS IN RBILD

The earlier reports of RBILD[1,5] suggested that the disease tended to improve with smoking cessation or steroid use, but this conclusion has changed over time, and the idea that smoking cessation or steroid therapy has any effect has recently been challenged.[6,7] Nonetheless, as indicated in Table 3, there is only 1 death thought to be related to interstitial lung disease in 78 patients with follow-up in the literature (1%), and most patients with RBILD don't get worse. But whether this stabilization is entirely stabilization of the interstitial lung disease is unclear because smoking cessation is known to decrease the rate of functional decline in COPD, and many of these patients clearly have COPD as well.

References

1. Myers JL, Veal CF Jr, Shin MS, Katzenstein AL. Respiratory bronchiolitis causing interstitial lung disease: a clinicopathologic study of six cases. *Am Rev Respir Dis.* 1987;135(4):880–884.
2. Davies G, Wells AU, du Bois RM. Respiratory bronchiolitis associated with interstitial lung disease and desquamative interstitial pneumonia. *Clin Chest Med.* 2004;25(4):717–726.
3. Wells AU, Nicholson AG, Hansell DM, du Bois RM. Respiratory bronchiolitis-associated interstitial lung disease. *Semin Respir Crit Care Med.* 2003;24(5):585–594.
4. Moon J, du Bois RM, Colby TV, Hansell DM, Nicholson AG. Clinical significance of respiratory bronchiolitis on open lung biopsy and its relationship to smoking related interstitial lung disease. *Thorax.* 1999;54(11):1009–1014.
5. Yousem SA, Colby TV, Gaensler EA. Respiratory bronchiolitis-associated interstitial lung disease and its relationship to desquamative interstitial pneumonia. *Mayo Clin Proc.* 1989;64(11):1373–1380.
6. Ryu JH, Myers JL, Capizzi SA, Douglas WW, Vassallo R, Decker PA. Desquamative interstitial pneumonia and respiratory bronchiolitis-associated interstitial lung disease. *Chest.* 2005;127(1):178–184.
7. Portnoy J, Veraldi KL, Schwarz MI, et al. Respiratory bronchiolitis-interstitial lung disease: long-term outcome. *Chest.* 2007;131(3):664–671.
8. Myers JL. Respiratory bronchiolitis with interstitial lung disease. *Semin Respir Med.* 1992;13:134–140.
9. Yousem SA. Respiratory bronchiolitis-associated interstitial lung disease with fibrosis is a lesion distinct from fibrotic nonspecific interstitial pneumonia: a proposal. *Mod Pathol.* 2006;19(11):1474–1479.
10. Niewoehner DE, Kleinerman J, Rice DB. Pathologic changes in the peripheral airways of young cigarette smokers. *N Engl J Med.* 1974;291(15):755–758.
11. Fraig M, Shreesha U, Savici D, Katzenstein AL. Respiratory bronchiolitis: a clinicopathologic study in current smokers, ex-smokers, and never-smokers. *Am J Surg Pathol.* 2002;26(5):647–653.
12. Hogg JC, Macklem PT, Thurlbeck WM. Site and nature of airway obstruction in chronic obstructive lung disease. *N Engl J Med.* 1968;278(25):1355–1360.
13. Cosio MG, Ghezzo H, Hogg JC, et al. The relations between structural changes in small airways and pulmonary-function tests. *N Engl J Med.* 1977;298(23):1277–1281.
14. Wright JL, Cosio MG, Wiggs BR, et al. A morphologic grading scheme for membranous and respiratory bronchioles. *Arch Pathol Lab Med.* 1985;109(2):163–165.
15. Wright JL, Lawson LM, Kennedy S, et al. The detection of small airways disease. *Am Rev Respir Dis.* 1984;129(6):989–994.
16. Cardoso W, Sekhon H, Hyde DM, et al. Collagen and elastin in human pulmonary emphysema. *Am Rev Respir Dis.* 1993;147(4):975–981.
17. Lang MR, Fiaux GW, Gillooly M, et al. Collagen content of alveolar wall tissue in emphysematous and non-emphysematous lungs. *Thorax.* 1994;49(4):319–326.
18. Lang MR, Fiaux GW, Hulmes DJS, et al. Quantitative studies of human lung airspace wall in relation to collagen and elastin content. *Matrix.* 1993;13(6):471–480.
19. Belton JC, Crise N, McLaughlin RF, et al. Ultrastructural alterations in collagen associated with microscopic foci of human emphysema. *Hum Pathol.* 1977;8(6):669–677.
20. Hogg JC, Nepszy SJ, Macklem PT, et al. Elastic properties of the centrilobular emphysematous space. *J Clin Invest.* 1969;48(7):1306–1312.
21. Remy-Jardin M, Remy J, Gosselin B, Becette V, Edme JL. Lung parenchymal changes secondary to cigarette smoking: pathologic-CT correlations. *Radiology.* 1993;186(3):643–651.
22. Heyneman LE, Ward S, Lynch DA, Remy-Jardin M, Johkoh T, Müller NL. Respiratory bronchiolitis, respiratory bronchiolitis-associated interstitial lung disease, and desquamative interstitial pneumonia: different entities or part of the spectrum of the same disease process? *AJR Am J Roentgenol.* 1999;173(6):1617–1622.
23. Gruden JF, Webb WR. CT findings in a proved case of respiratory bronchiolitis. *AJR Am J Roentgenol.* 1993;161(1):44–46.
24. Park JS, Brown KK, Tuder RM, Hale VA, King TE Jr, Lynch DA. Respiratory bronchiolitis-associated interstitial lung disease: radiologic features with clinical and pathologic correlation. *J Comput Assist Tomogr.* 2002;26(1):13–20.
25. Holt RM, Schmidt RA, Godwin JD, Raghu G. High resolution CT in respiratory bronchiolitis-associated interstitial lung disease. *J Comput Assist Tomogr.* 1993;17(1):46–50.
26. Dowson LJ, Guest PJ, Stockley RA. Longitudinal changes in physiological, radiological, and health status measurements in α1-antitrypsin deficiency and factors associated with decline. *Am J Respir Crit Care Med.* 2001;164(10, pt 1):1805–1809.
27. Dowson LJ, Guest PJ, Hill SL, Holder RL, Stockley RA. High-resolution computed tomography scanning in α1-antitrypsin deficiency: relationship to lung function and health status. *Eur Respir J.* 2001;17(6):1097–1104.
28. Gelb AF, Zamel N, Hogg JC, Muller NL, Schein JL. Pseudophysiologic emphysema resulting from severe small-airways disease. *Am J Respir Crit Care Med.* 1998;158(3):815–819.

Downloaded from https://aplm.kglmeridian.com at 2026-03-06 via free access